

## REVIEW ARTICLE

## CURRENT CONCEPTS

## Acute Cardiac Tamponade

David H. Spodick, M.D., D.Sc.

From the Division of Cardiovascular Medicine, Department of Medicine, Saint Vincent Hospital—Worcester Medical Center, Worcester, Mass.

N Engl J Med 2003;349:684-90.  
Copyright © 2003 Massachusetts Medical Society.

**C**ARDIAC TAMPONADE IS LIFE-THREATENING, SLOW OR RAPID COMPRESSION of the heart due to the pericardial accumulation of fluid, pus, blood, clots, or gas, as a result of effusion, trauma, or rupture of the heart.<sup>1,2</sup> Because the causes of pericardial disease<sup>1</sup> and thus of tamponade are diverse, clinicians must choose the most probable diagnosis, always anticipating surprises. Thus, traumatic tamponade is most apt to follow cardiac surgery, and tuberculous tamponade is relatively common in Africa but rare in the United States.

Understanding the physiological changes produced by tamponade is essential to diagnosis and treatment.<sup>3-12</sup> The primary abnormality is rapid or slow compression of all cardiac chambers as a result of increasing intrapericardial pressure. The pericardial contents first reach the limit of the pericardial reserve volume<sup>6</sup> — the volume that would just distend the pericardium — and the rate of expansion then increases, soon exceeding that of pericardial stretch. Although the pericardium stretches normally over time, at any instant it is inextensible, making the heart compete with the increased pericardial contents for the fixed intrapericardial volume.<sup>6,10</sup> As the chambers become progressively smaller and myocardial diastolic compliance is reduced, cardiac inflow becomes limited, ultimately equalizing mean diastolic pericardial and chamber pressures.<sup>1-3</sup> Key elements are the rate of fluid accumulation relative to pericardial stretch and the effectiveness of compensatory mechanisms. Thus, intrapericardial hemorrhage from wounds or cardiac rupture occurs in the context of a relatively stiff, unyielding pericardium and quickly overwhelms the pericardial capacity to stretch before most compensatory mechanisms can be activated, whereas in the case of a slow increase in pericardial volume as a result of inflammation, 2 liters or more may accumulate before critical, life-threatening tamponade occurs.<sup>13</sup>

The stiffness of the pericardium determines fluid increments precipitating tamponade, as illustrated by characteristic pericardial pressure–volume (strain–stress) curves (Fig. 1): there is an initial slow ascent, followed by an almost vertical rise.<sup>2</sup> This steep rise makes tamponade a “last-drop” phenomenon: the final increment produces critical cardiac compression, and the first decrement during drainage produces the largest relative decompression.

The true filling pressure is the myocardial transmural pressure, which is intracardiac minus pericardial pressure.<sup>14</sup> Rising pericardial pressure reduces and ultimately offsets this transmural pressure, first for the right heart and ultimately for all chambers. On average, during inspiration and expiration, the right heart increases its filling at the expense of the left, so that its transmural pressure transiently improves and then reverts during expiration.<sup>1,2,14</sup> In florid tamponade such a mechanism cannot compensate for reduced stroke volumes, since these volumes depend on the elements that protect cardiac output and arterial pressures, principally beta-adrenergically increased heart rate, peripheral resistance and ejection fractions, and given sufficient time, expansion of the blood volume. Additional compensation provided by neurohormonal stimulation is similar to that occurring in heart failure,<sup>15</sup> except that the levels of atrial natriuretic peptide do

not increase because the compressed myocardium cannot stretch.<sup>16</sup>

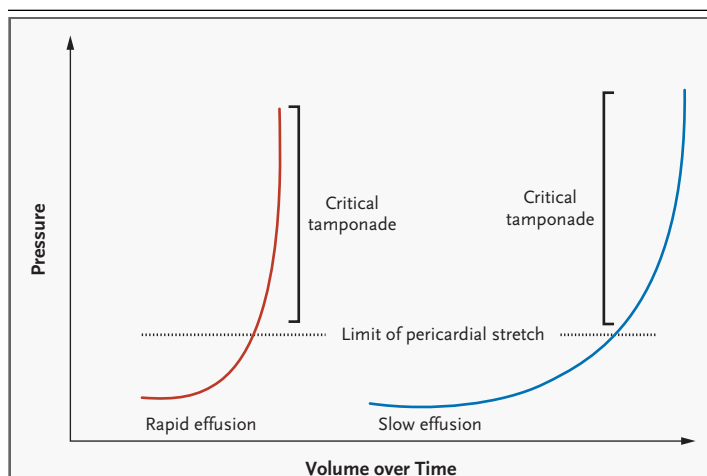
Acute tamponade thus reflects decompensation as patients reach the steep portion of the pressure–volume curve (Fig. 1). Moreover, intercurrent factors can cause the decompensation of any effusion—for example, the influx of blood, effusion-expanding osmotic effects of fragmenting intrapericardial clots, or inflammatory stiffening of the pericardium.<sup>1,17,18</sup> Finally, although coronary blood flow is reduced in tamponade, there is no ischemic component because coronary flow remains proportional to the reduced work and operational requirements of the heart.<sup>8</sup>

#### CLINICAL FINDINGS

Critical tamponade is a form of cardiogenic shock, and the differential diagnosis may initially be elusive. Since most symptoms are nonspecific, tamponade must be suspected in many contexts—for example, in patients who have wounds of the chest or upper abdomen and hypotension or in those who have hypotension preceded by symptoms of an inciting pericardial disease, such as chest discomfort and pleuritic pain. Tachypnea and dyspnea on exertion that progresses to air hunger at rest are the key symptoms, but it may not be possible to obtain such information from patients who are unconscious or obtunded or who have convulsions at presentation. Most patients are weak and faint at presentation and can have vague symptoms such as anorexia, dysphagia, and cough.<sup>1</sup> The initial symptom may also be one of the complications of tamponade, such as renal failure.<sup>19</sup>

Most physical findings are equally nonspecific.<sup>1,19</sup> Tachycardia (a heart rate of more than 90 beats per minute) is the rule. Exceptions include patients with bradycardia during uremia and patients with hypothyroidism. Contrary to common belief, a pericardial rub is a frequent finding in patients with inflammatory effusions.<sup>20</sup> Heart sounds may be attenuated owing to the insulating effects of the pericardial fluid and to reduced cardiac function. Although the precordium may seem quiet, an apical beat is frequently palpable, and patients with preexisting cardiomegaly or anterior and apical pericardial adhesions may have active pulsations.

Clinically significant tamponade usually produces absolute or relative hypotension; in rapid tamponade, patients are often in shock, with cool arms and legs, nose, and ears and sometimes peripheral



**Figure 1. Cardiac Tamponade.**

Pericardial pressure–volume (or strain–stress) curves are shown in which the volume increases slowly or rapidly over time. In the left-hand panel, rapidly increasing pericardial fluid first reaches the limit of the pericardial reserve volume (the initial flat segment) and then quickly exceeds the limit of parietal pericardial stretch, causing a steep rise in pressure, which becomes even steeper as smaller increments in fluid cause a disproportionate increase in the pericardial pressure. In the right-hand panel, a slower rate of pericardial filling takes longer to exceed the limit of pericardial stretch, because there is more time for the pericardium to stretch and for compensatory mechanisms to become activated.

cyanosis. Jugular venous distention is the rule, with peripheral venous distention in the forehead, scalp, and ocular fundi unless the patient has hypovolemia. Thus, rapid tamponade, especially acute hemopericardium, may produce exaggerated jugular pulsations without distention, because there is insufficient time for blood volume to increase. Venous waves usually lack the normal early diastolic y descent. In compressive pericardial disease (tamponade and constriction), venous waves are not outward pulsations; rather, x and y collapse from a high standing pressure level.<sup>1</sup>

A key diagnostic finding, pulsus paradoxus<sup>21</sup>—conventionally defined as an inspiratory systolic fall in arterial pressure of 10 mm Hg or more during normal breathing—is often palpable in muscular arteries. With very low cardiac output, however, a catheter is needed to identify pulsus paradoxus. Other conditions causing pulsus paradoxus include massive pulmonary embolism, profound hemorrhagic shock, other forms of severe hypotension, and obstructive lung disease. Moreover, certain conditions can impede the identification of tamponade by making pulsus paradoxus undetectable (Table 1).

## LABORATORY INVESTIGATIONS

Cardiac catheterization will show equilibration of average diastolic pressure and characteristic respiratory reciprocation of cardiac pressures: an inspiratory increase on the right and a concomitant decrease on the left—the proximate cause of pulsus paradoxus. Except in low-pressure tamponade, diastolic pressures throughout the heart are usually 15 to 30 mm Hg. These are similar to pressures present in heart failure, but for unknown reasons, tamponade does not cause alveolar pulmonary edema.<sup>16</sup> Although any type of large cardiac silhouette in a patient with clear lung fields should suggest the presence of pericardial effusion, chest films may not be helpful initially, since at least 200 ml of fluid must accumulate before the cardiac silhouette is affected. In the lateral film, definite pericardial-fat

lines are uncommon but are highly specific for large effusions.<sup>19</sup>

An electrocardiogram may show signs of pericarditis, but the only quasispecific sign of tamponade is electrical alternation,<sup>22</sup> which may affect any or all<sup>23</sup> electrocardiographic waves or only the QRS. If the QRS complex is affected, every other QRS complex is of smaller voltage, often with reversed polarity. Combined P and QRS alternation is virtually specific for tamponade.<sup>1</sup> In rare cases, very large effusions, even without tamponade, cause QRS alternation. Echocardiography reveals its mechanism: swinging of the heart (Fig. 2).<sup>23,24</sup> The volume of most nonhemorrhagic effusions that cause tamponade is moderate to large (300 to 600 ml).

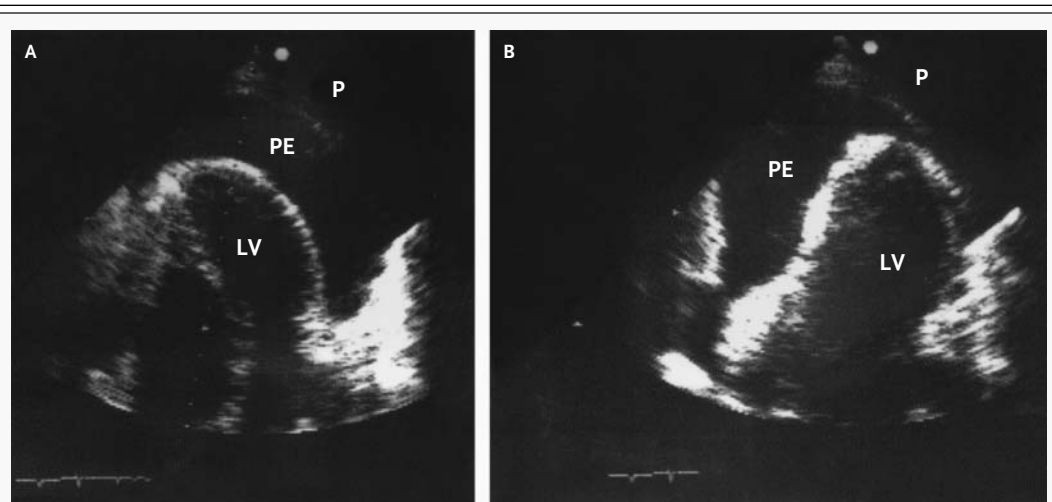
Doppler echocardiography is the principal tool for diagnosing pericardial effusion and cardiac tamponade. Computed tomography (CT) and magnetic resonance imaging are often less readily available and are generally unneeded unless Doppler echocardiography is not feasible. In the absence of myocardial disease or injury, echocardiography demonstrates the usually circumferential fluid layer and compressed chambers with high ventricular ejection fractions.<sup>24</sup> Doppler study discloses marked respiratory variations in transvalvular flows. One mechanism of pulsus paradoxus is visible: on inspiration, both the ventricular and atrial septa move sharply leftward, reversing on expiration<sup>1</sup>; in other words, each side of the heart fills at the expense of the other, owing to the fixed intrapericardial volume. The inferior vena cava is dilated, with little or no change on respiration.

Among echocardiographic signs, the most characteristic, although they are not entirely specific, are chamber collapses, which are nearly always of the right atrium and ventricle. During early diastole, the right ventricular free wall invaginates, and at end diastole, the right atrial wall invaginates.<sup>25</sup> Right ventricular collapse is a less sensitive but more specific finding for tamponade, whereas right atrial collapse is more specific if inward movement lasts for at least 30 percent of the cardiac cycle. Right atrial collapse may be seen in patients with hypovolemia who do not have tamponade. In about 25 percent of patients, the left atrium also collapses, and this finding is highly specific for tamponade. Left ventricular collapse usually occurs under special conditions such as localized postsurgical tamponade. These wall changes occur when respective chamber pressures temporarily fall below the pericardial pressure.<sup>24,25</sup>

**Table 1. Conditions Leading to the Absence of Diagnostic Pulsus Paradoxus in Cardiac Tamponade.**

Condition	Consequence
Extreme hypotension, as in shock, and even severe tamponade	May make respiration-induced pressure changes unmeasurable
Acute left ventricular myocardial infarction with occasional effusion causing tamponade	—
Pericardial adhesions, especially over the right heart	Volume changes impeded
Local (usually postsurgical) pericardial adhesions	Local cardiac compression by loculated fluid
Pulmonary vein and left ventricular diastolic pressures and left ventricular stiffness markedly exceed those of the right ventricle*	Reduced effects of respiration on right-heart filling
Right ventricular hypertrophy without pulmonary hypertension	Causes right-sided resistance to the effects of breathing
Severe aortic regurgitation, with or without severe left ventricular dysfunction	Produces sufficient regurgitant flow to damp down respiratory fluctuations
Atrial septal defects	Increased inspiratory venous return balanced by shunting to the left atrium
Some cases of low-pressure tamponade	Makes marked respiratory changes in blood pressure diagnostically insignificant

\* In patients with marked left ventricular hypertrophy or severe left-sided heart failure, pericardial pressure effectively equilibrates only with right heart pressures, a form of right ventricular tamponade, with the much less compliant left ventricle resisting passively changing pericardial pressure. Under these conditions, respiratory changes cannot alternately favor right- and left-sided filling.



**Figure 2. Swinging of the Heart with a Large Pericardial Effusion (PE), Causing Electrical Alternation and Consequent Tamponade.**

Apical four-chamber two-dimensional echocardiograms show the extremes of oscillation and the resultant effect on the QRS complex. In Panel A, the heart swings to the right, and lead II shows a small QRS complex. In Panel B, the heart swings to the left, and the QRS complex is larger. P denotes pericardium, and LV left ventricle.

#### VARIANT FORMS OF CARDIAC TAMPONADE

Low-pressure tamponade occurs at diastolic pressures of 6 to 12 mm Hg and is virtually confined to patients with hypovolemia and severe systemic diseases, hemorrhage, or cancer, or in patients with hypovolemia after diuresis.<sup>19</sup> Patients are weak and generally normotensive, with dyspnea on exertion and no diagnostic pulsus paradoxus, but with characteristic respiratory fluctuations in transvalvular diastolic Doppler flows. The low-pressure effusion equilibrates only with right-sided diastolic pressures and does so at first only during inspiration (“inspiratory tracking”).<sup>1,3</sup> A fluid challenge with a liter of warm saline can evoke tamponade dynamics.<sup>26</sup>

Hypertensive cardiac tamponade<sup>27</sup> with all the classic features of tamponade, occurs at high and very high arterial blood pressures (even over 200 mm Hg)<sup>27</sup> and is ascribed to excessive beta-adrenergic drive. Affected patients typically have had antecedent hypertension.

Regional cardiac tamponade<sup>19,24</sup> occurs when any cardiac zone is compressed by loculated effusions, which are usually accompanied by localized

pericardial adhesions, especially after cardiac surgery. Sometimes the typical hemodynamic abnormalities are found only in the compressed chambers or zones. However, loculation can also produce classic tamponade, presumably by tightening the uninvolved pericardium; for example, loculated effusions after cardiac surgery may include hematomas over the right atrium and atrioventricular groove.<sup>28</sup> Localized right atrial tamponade may also cause right-to-left shunting through a patent foramen ovale or an atrial septal defect.<sup>29</sup>

After right ventricular infarction, loculated effusion can cause selective right-heart tamponade in which right atrial pressure is higher than left atrial pressure.<sup>28</sup> The absence of pulsus paradoxus (Table 1) makes this form difficult to recognize. Effusive-constrictive pericarditis is characterized by mixed clinical, imaging, and hemodynamic signs, because a constrictive epicarditis underlies the pericardial effusion. In some patients with scarred, rigid parietal and visceral pericardium, tamponade can occur with relatively little accumulation of fluid. Effusive-constrictive pericarditis is revealed in these patients when drainage of pericardial fluid does not cause intracardiac pressures to return to normal.<sup>30,31</sup>

## SPECIAL PROBLEMS

Postoperative tamponade,<sup>28</sup> which is more frequent after valve surgery than after coronary-artery bypass surgery and is more frequent with postoperative anticoagulant therapy, is due to trauma-induced pericardial effusion and bleeding. Since some degree of pericarditis occurs after every cardiac operation,<sup>28</sup> and most patients have a small, seemingly benign effusion postoperatively, it is not surprising that tamponade eventually occurs in some. Postoperative myocardial stiffness, variable fluid–electrolyte abnormalities, and hemorrhage tend to preclude the appearance of classic signs such as pulsus paradoxus (Table 1); thus, when tamponade is suspected postoperatively, prompt imaging — particularly Doppler echocardiography — is necessary. Late tamponade, occurring more than five days postoperatively,<sup>32</sup> must be suspected in any patient in whom hypotension develops. Primary care physicians may not be familiar with tamponade, and if it occurs very late (two weeks or more) after surgery, they may not suspect it. Some episodes of late hemorrhage may be delayed because the rates of bleeding are relatively slow and intrapericardial clotting complicates diagnosis and management.

MANAGEMENT OF ACUTE  
CARDIAC TAMPONADE

The treatment of cardiac tamponade is drainage of the pericardial contents, preferably by needle paracentesis<sup>19</sup> (Fig. 3) with the use of echocardiographic or another type of imaging, such as fluoroscopy or CT. The needle tip is evident on imaging, and imaging can thus safely be used to identify the optimal point at which to penetrate the pericardium.<sup>33</sup> Drainage may be performed in the catheterization laboratory when the diagnosis is uncertain or effusive constrictive pericarditis is possible. However, sudden circulatory collapse warrants the use of pericardiocentesis without imaging, since further decompensation may occur without warning. If the heart cannot be reached by a needle or catheter, surgical drainage is required, usually through a subcostal incision. Surgical drainage is desirable in patients with intrapericardial bleeding and in those with clotted hemopericardium or thoracic conditions that make needle drainage difficult or ineffective.<sup>34</sup> Subcritical uremic tamponade often responds to intensified renal dialysis, but if this approach is unsuccessful, drainage is required.

Recurrences, especially in patients with malignant tamponade, may require balloon pericardiectomy through the use of special catheters that create “windows” between the pericardium and the absorbing surface of the pleura or peritoneum.<sup>32</sup> Death in patients with tamponade is usually heralded by pulseless electrical activity<sup>19</sup>: the electrocardiogram continues to register complexes in the absence of blood flow or pressure.

Medical treatment of acute cardiac tamponade, including inotropic support with or without vasodilators,<sup>17</sup> is relatively controversial<sup>35</sup> and is aimed at supporting compensatory mechanisms to reduce the elevated vascular resistance. Thus, dobutamine, administered to reverse the hypotension, is theoretically ideal.<sup>3,11,13</sup> During tamponade, however, endogenous inotropic stimulation of the heart is often already maximal.

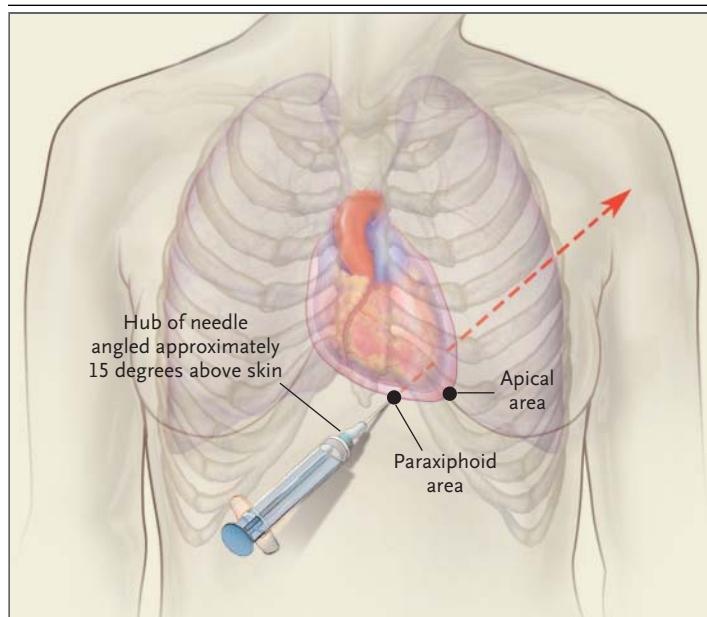
The approach to medical therapy has been based on studies in animals. However, these results are the subject of controversy, since in short-term surgical experiments in anesthetized animals, the presence of myocardial depression causes almost any measure to improve function.<sup>7,12,35</sup> Studies in intact, unanesthetized animals with indwelling instruments and euvolemia have yielded different results that have cast doubt on the value of various approaches, especially volume infusion.<sup>7,12,35</sup> Indeed, increasing the volume may help only in patients with hypovolemia, since in patients with normovolemia and hypervolemia, volume infusion may increase intracardiac pressures as well as heart size, which in turn increases pericardial pressure, further reducing or eliminating the low transmural myocardial pressures supporting the circulation.<sup>7,12,19</sup> Moreover, intravenous administration of resuscitative fluid can precipitate tamponade.<sup>36</sup>

An opioid mechanism contributes to the hypotension of cardiac tamponade; experiments in animals show that naloxone counteracts the hypotension,<sup>12</sup> but this approach has not been used clinically.

Mechanical ventilation with positive airway pressure should be avoided in patients with tamponade, because this further decreases cardiac output.<sup>19</sup> In patients with cardiac arrest and a large amount of pericardial fluid, external cardiac compression has little or no value, because there is little room for additional filling and because even if systolic pressure rises, diastolic pressure falls and, in doing so, reduces coronary perfusion pressure.<sup>36</sup>

## PERICARDIOCENTESIS

Needle drainage of pericardial fluid, whether or not it is done on an emergency basis (e.g., in a patient in rapidly worsening hemodynamic condition), requires the clinician to select a point on the patient's chest or epigastrium to insert the needle. This is best done with imaging, as already discussed, to determine which anterior landmarks, usually paraxiphoid or apical, are closest to the fluid. The paraxiphoid approach is also most often used for pericardiocentesis that is performed without imaging.<sup>1</sup> Common points of access are illustrated in Figure 3. The needle is usually inserted between the xiphoid process and the left costal margin; in patients with tough skin, a small nick may be made first with a scalpel. The needle is inserted at a 15-degree angle to bypass the costal margin, and then its hub is depressed so that the point is aimed toward the left shoulder. The needle is then advanced slowly, until the pericardium is pierced and fluid is aspirated. Electrocardiography should not be used to monitor the patient's condition, since attaching an electrode to the needle may provide misleading results.<sup>1</sup> The use of a 16-gauge to 18-gauge polytetrafluoroethylene-sheathed needle facilitates the process, since its steel core can be withdrawn once the pericardium has been breached, leaving only the sheath in the pericardial space. For prolonged drainage, a guide wire passed through the sheath will facilitate the introduction of a pigtail angiographic catheter. Thereafter, patients should be followed with the



**Figure 3. Most Common Sites of Blind and Image-Guided Insertion of the Needle for Pericardiocentesis.**

In the paraxiphoid approach, the needle should be aimed toward the left shoulder. In the apical approach, the needle is aimed internally.

use of Doppler echocardiography to ensure that the pericardial space has been adequately drained and to avert a recurrence. When the amount of fluid drained is less than 50 ml a day, the catheter may be withdrawn; the patient should continue to be observed.

## REFERENCES

- Spodick DH. Pericardial diseases. In: Braunwald E, Zipes DP, Libby P, eds. *Heart disease: a textbook of cardiovascular medicine*. 6th ed. Vol. 2. Philadelphia: W.B. Saunders, 2001:1823-76.
- Shabetai R. Diseases of the pericardium. In: Schlant RC, Alexander RW, eds. *Hurst's the heart: arteries and veins*. 6th ed. Vol. 1. New York: McGraw-Hill, 1994:1647-74.
- Reddy PS, Curtiss EI, Uretsky BF. Spectrum of hemodynamic changes in cardiac tamponade. *Am J Cardiol* 1990;66:1487-91.
- Beloucif S, Takata M, Shimada M, Robotham JL. Influence of pericardial constraint on atrioventricular interactions. *Am J Physiol* 1992;263:H125-H134.
- Friedman HS, Lajam F, Zaman Q, et al. Effect of autonomic blockade on the hemodynamic findings in acute cardiac tamponade. *Am J Physiol* 1977;232:H5-H11.
- Spodick DH. Threshold of pericardial constraint: the pericardial reserve volume and auxiliary pericardial functions. *J Am Coll Cardiol* 1985;6:296-7.
- Cogswell TL, Bernath GA, Keelan MH Jr, Wann LS, Klopfenstein HS. The shift in the relationship between intrapericardial fluid pressure and volume induced by acute left ventricular pressure overload during cardiac tamponade. *Circulation* 1986;74:173-80.
- Grose R, Greenberg MA, Yipintsoi T, Cohen MV. Cardiac tamponade in dogs with normal coronary arteries. I. Effect of changing intravascular volume on hemodynamics and myocardial blood flow. *Basic Res Cardiol* 1984;79:531-41.
- Hurrell DG, Symanski JD, Chaliki HP, Klarich KW, Pascoe RD, Nishimura RA. Assessment of right atrial pressure by hepatic vein Doppler echocardiography: a simultaneous catheterization/Doppler echocardiographic study. *J Am Coll Cardiol* 1996;27: Suppl A:212A. abstract.
- Santamore WP, Li KS, Nakamoto T, Johnston WE. Effects of increased pericardial pressure on the coupling between the ventricles. *Cardiovasc Res* 1990;24:768-76.
- Martins JB, Manuel WJ, Marcus ML, Kerber RE. Comparative effects of catecholamines in cardiac tamponade: experimental and clinical studies. *Am J Cardiol* 1980;46:59-66.
- Klopfenstein HS, Mathias DW. Influence of naloxone on response to acute cardiac tamponade in conscious dogs. *Am J Physiol* 1990;259:H512-H517.
- Reddy PS, Curtiss EI, O'Toole JD, Shaver JA. Cardiac tamponade: hemodynamic observations in man. *Circulation* 1978;58:265-72.
- Boltwood CM Jr. Ventricular performance related to transmural filling pressure in clinical cardiac tamponade. *Circulation* 1987;75:941-55.
- Schrier RW, Abraham WT. Hormones and hemodynamics in heart failure. *N Engl J Med* 1999;341:577-85.
- Spodick DH. Low atrial natriuretic factor levels and absent pulmonary edema in pericardial compression of the heart. *Am J Cardiol* 1989;63:1271-2.
- Gascho JA, Martins JB, Marcus ML, Ker-

- ber RE. Effects of volume expansion and vasodilators in acute pericardial tamponade. *Am J Physiol* 1981;240:H49-H53.
18. Spodick DH. The normal and diseased pericardium: current concepts of pericardial physiology, diagnosis and treatment. *J Am Coll Cardiol* 1983;1:240-51.
19. Cooper JP, Oliver RM, Currie P, Walker JM, Swanton RH. How do the clinical findings in patients with pericardial effusions influence the success of aspiration? *Br Heart J* 1995;73:351-4.
20. Spodick DH. Pericardial rub: prospective, multiple observer investigation of pericardial friction in 100 patients. *Am J Cardiol* 1975;35:357-62.
21. Shabetai R. Pericardial and cardiac pressure. *Circulation* 1988;77:1-5.
22. Spodick DH. Truly total electric alternation of the heart. *Clin Cardiol* 1998;21:427-8.
23. *Idem*. Electric alternation of the heart: its relation to the kinetics and physiology of the heart during cardiac tamponade. *Am J Cardiol* 1962;10:155-65.
24. D'Cruz I, Rehman AU, Hancock HI. Quantitative echocardiographic assessment in pericardial disease. *Echocardiography* 1997;14:207-14.
25. Reydel B, Spodick DH. Frequency and significance of chamber collapses during cardiac tamponade. *Am Heart J* 1990;119:1160-3.
26. Angel J, Anivarro I, Domingo E, Soler-Soler J. Cardiac tamponade: risk and benefit of fluid challenge performed while waiting for pericardiocentesis. *Circulation* 1997;96: Suppl I:I-30. abstract.
27. Ramsaran EK, Benotti JR, Spodick DH. Exacerbated tamponade: deterioration of cardiac function by lowering excessive arterial pressure in hypertensive cardiac tamponade. *Cardiology* 1995;86:77-9.
28. Bommer WJ, Follette D, Pollock M, Arena F, Bognar M, Berkoff H. Tamponade in patients undergoing cardiac surgery: a clinical-echocardiographic diagnosis. *Am Heart J* 1995;130:1216-23.
29. Thompson RC, Finck SJ, Leventhal JP, Safford RE. Right-to-left shunt across a patent foramen ovale caused by cardiac tamponade: diagnosis by transesophageal echocardiography. *Mayo Clin Proc* 1991;66:391-4.
30. Spodick DH, Kumar R. Subacute constrictive pericarditis with cardiac tamponade. *Dis Chest* 1968;54:62-6.
31. Hancock EW. Subacute effusive-constrictive pericarditis. *Circulation* 1971;43:183-92.
32. Pepi M, Muratori M, Barbier P, et al. Pericardial effusion after cardiac surgery: incidence, site, size, and haemodynamic consequences. *Br Heart J* 1994;72:327-31.
33. Callahan JA, Seward JB. Pericardiocentesis guided by two-dimensional echocardiography. *Echocardiography* 1997;14:497-504.
34. Merce J, Sagrista-Sauleda J, Permyer-Miralda G, Soler-Soler J. Should pericardial drainage be performed routinely in patients who have a large pericardial effusion without tamponade? *Am J Med* 1998;105:106-9.
35. Spodick DH. Medical treatment of cardiac tamponade. In: Caturelli G, ed. *Cura intensiva cardiologica*. Rome: TIPAR Poligrafica, 1991:265-8.
36. Hashim R, Frankel H, Tandon M, Rabinovici R. Fluid resuscitation-induced cardiac tamponade. *Trauma* 2002;53:1183-4.

Copyright © 2003 Massachusetts Medical Society.

#### IMAGES IN CLINICAL MEDICINE

The Journal welcomes consideration of new submissions for Images in Clinical Medicine. Instructions for authors and procedures for submissions can be found on the Journal's Web site at <http://www.nejm.org>. At the discretion of the editor, images that are accepted for publication may appear in the print version of the Journal, the electronic version, or both.